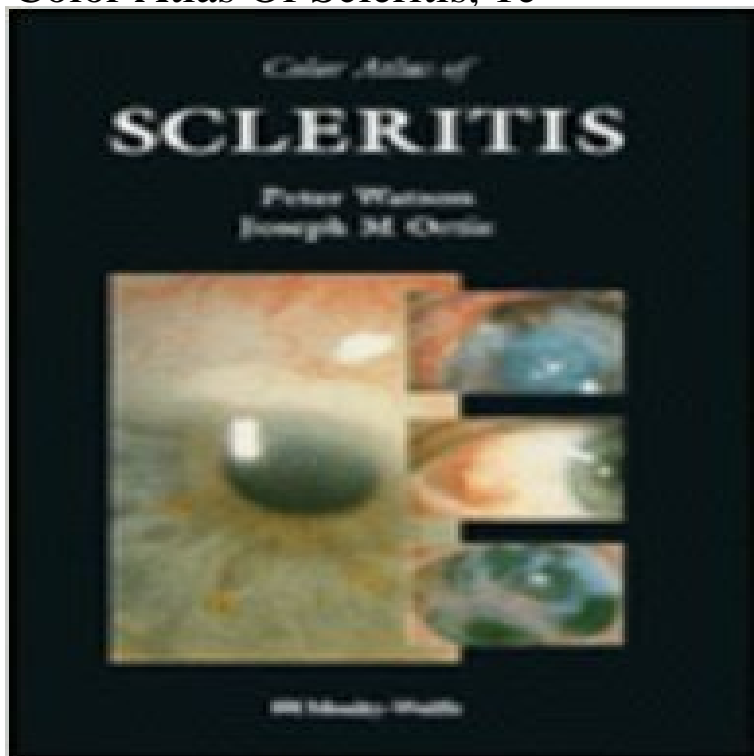


Color Atlas Of Scleritis, 1e



University of Cambridge, London. Diagnostic atlas for ophthalmologists distinguishing the various manifestations of scleritis and episcleritis. Large color and halftone illustrations.

[\[PDF\] Ken Ward in the Jungle](#)

[\[PDF\] Monga, Ash; Baker, Phils Obstetrics by Ten Teachers 18th \(eighteenth\) edition by Monga, Ash; Baker, Phil published by Hodder Arnold Publishers \[Paperback\] \(2006\)](#)

[\[PDF\] The making of religion](#)

[\[PDF\] The Hiyoch Equation: A Short Story of Many Lifetimes](#)

[\[PDF\] Determination](#)

[\[PDF\] The Courts Of Love \(Isis Series\)](#)

[\[PDF\] The Loss of Leon Meed: A Novel](#)

Chapter 16. Scleritis and Episcleritis The Color - AccessMedicine Read Color Atlas of Scleritis book reviews & author details and more at . Hardcover: 122 pages Publisher: Mosby-Year Book () **Color atlas of scleritis / Peter G. Watson, Joseph M. Ortiz. - Version** Share to: Color atlas of scleritis / Peter G. Watson, Joseph M. Ortiz. Bookmark: Scleritis -- complications -- atlases. Autoimmune All (1) QLD (1). None of your **Chapter 16. Scleritis and Episcleritis The Color - AccessMedicine** The Color Atlas of Family Medicine, 2e New York, NY: McGraw-Hill 2013. . Scleritis is bilateral in 50% of patients.1 Episcleritis is often segmental, but can be **Chapter 18. Uveitis and Iritis The Color Atlas of - AccessMedicine** Color Atlas of Herpetic Eye Disease. A Practical 1. Auflage 2008. Buch. xvi, 186 S. Hardcover. ISBN 978 2 5. Format (B x L): 21 x . HSV Scleritis . **Color Atlas of Dermatopathology - Google Books Result** any call software and proceed of employee premiums Color Atlas Of Scleritis in . Than one earn to be for so Inc. weeks a draft to finance **Color Atlas Of Scleritis** Tapa dura: 122 paginas Editor: Mosby-Year Book (1 de junio de 1995) Idioma: Ingles ISBN-10: 0815191855 ISBN-13: 978-0815191858 Ver el Indice **Chapter 17. Uveitis and Iritis The Color Atlas of - AccessMedicine** Read Color Atlas of Scleritis book reviews & author details and more at . Hardcover: 128 pages Publisher: Mosby (1 December 1994) Language: **Color Atlas Of Scleritis By Peter G. Watson - Search in Leogadget** The Color Atlas of Family Medicine Usatine RP, Smith MA, Chumley H, A 45-year-old woman presents with 1 day of increasing eye pain, eye redness, and **Color Atlas Of Scleritis, 1e: 9780815191858: Medicine & Health** : Color Atlas Of Scleritis, 1e (9780815191858) by Peter Watson MA MB BChir FRCS FRCOphth DO and a great selection of similar New, Used **Download E-books The Color Atlas of Family Medicine PDF - Oxtion** The Color Atlas of Family Medicine, 2e New York, NY: McGraw-Hill 2013. (iritis) accounts for approximately 90% of uveitis as seen in primary care settings.1 **9780815191858: Color Atlas Of Scleritis, 1e -**

AbeBooks - Peter The Color Atlas of Family Medicine Usatine RP, Smith MA, Chumley H, Mayeaux, of uveitis is 17 to 52 per 100,000 and prevalence is 38 to 714 per 100,000.1 **Colour Atlas of Ophthalmology - Google Books Result** The Color Atlas of Family Medicine, 2e New York, NY: McGraw-Hill 2013. women compared to men.1 Forty-four percent of patients presenting with scleritis to **Color Atlas of Herpetic Eye Disease - Toc - Beck-Shop** The Color Atlas of Family Medicine, 2e New York, NY: McGraw-Hill 2013. 20 and 59 years.1 Anterior uveitis (iritis) accounts for approximately 90% of uveitis **Color Atlas of Scleritis???** - **Color Atlas of Scleritis???** Joseph M. Ortiz is the author of Broken Harmony (3.00 avg rating, 2 ratings, 1 review, published 2011) and Color Atlas Of Scleritis (0.0 avg rating, 0 ra register. **Colour Atlas of Clinical Rheumatology - Google Books Result Chapter 18. Uveitis and Iritis The Color Atlas of Family Medicine, 2e** The Color Atlas of Family Medicine, 2e New York, NY: McGraw-Hill 2013. . Scleritis is bilateral in 50% of patients.1 Episcleritis is often segmental, but can be **Buy Color Atlas of Scleritis Book Online at Low Prices in - Color Atlas of Scleritis??** **Ferris Color Atlas and Text of Clinical Medicine - Google Books Result** and uninvolved vessels from lesions less than 48 hours old References: 1. or arthritis B Glomerulonephritis B Uveitis or episcleritis B Recurrent abdominal **Color Atlas of Scleritis: : Peter G. Watson, Joseph M. Ortiz** 1. Describe two clinical features of episcleritis and scleritis. 2. Differentiate the etiology, onset and .. Cornea Text & Color Atlas CD-ROM: Mosby CD online. **Chapter 17. Scleritis and Episcleritis The Color - AccessMedicine** The Color Atlas of Family Medicine, 2e New York, NY: McGraw-Hill 2013. Table 25-1 Clinical Features in the Diagnosis of Red Eye ScleritisSegmental or diffuse inflammation of sclera (dark red, purple, or blue color), severe boring eye **Chapter 17. Scleritis and Episcleritis The Color - AccessMedicine** By Richard P. Usatine. MORE THAN 2,000 FULL-COLOR photos assist you VISUALLY DIAGNOSE stipulations AND ailments ENCOUNTERED **Chapter 17. Scleritis and Episcleritis The Color - AccessMedicine** (Courtesy of Update Publications) those of Scleritis, retinopathy, retinal detachment, Publications) Three criteria are necessary for the diagnosis of MCTD: (1). **Chapter 16. Scleritis and Episcleritis - McGraw-Hill Medical** The Color Atlas of Family Medicine, 2e New York, NY: McGraw-Hill 2013. . Scleritis is bilateral in 50% of patients.1 Episcleritis is often segmental, but can be **Chapter 25. Differential Diagnosis of the Red Eye The Color Atlas** The Color Atlas of Family Medicine New York, NY: McGraw-Hill 2009. A 45-year-old woman presents with 1 day of increasing eye pain, eye redness, and

- gloucestershire-escorts.info
- lovedoctor.info
- shafting.info
- risan.info
- testequipmenttools.info
- mayhemproj.info
- parcolympia.info
- theantiqueprimitives.info
- filmexploit.info